

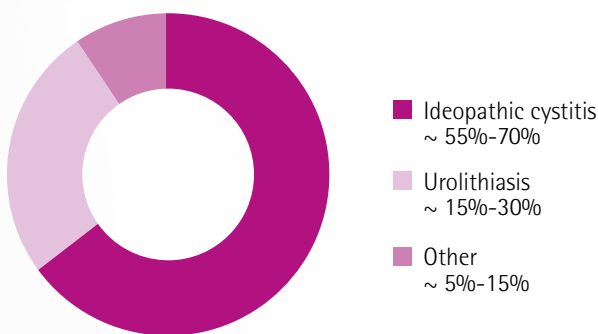
This article summarizes the case studies provided by Drs Ducluzaux, Dr Pereira, dr Nègre, Dr Fradin-Fermé and Dr Baril.

PURINA® PRO PLAN® Veterinary Diets Feline UR S7/Ox Urinary. Proven efficacious in general practice in the management of FLUTD in cats

The most common causes of FLUTD in cats are idiopathic cystitis and urolithiasis (struvite, calcium oxalate) which together account for up to 90% of FLUTD cases.

Feline UR S7/Ox Urinary provides veterinary surgeons with a simple, unique, nutritional solution for all common FLUTD cases, regardless of cause. Numerous case studies from practitioners confirm its efficacy in managing idiopathic cystitis and urolithiasis (struvite and calcium oxalate). This article summarizes real case studies from practice to illustrate the benefits of Feline UR S7/Ox Urinary to cats with FLUTD caused by the three main aetiologies.

APPROXIMATE FREQUENCY OF CAUSES OF FLUTD



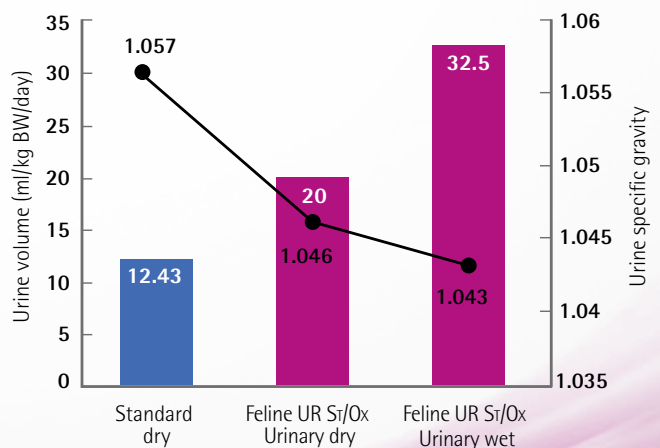
Feline UR S7/Ox is beneficial for cases of idiopathic cystitis

Idiopathic cystitis is, by definition, a lower urinary tract condition of unknown cause. However it does appear to be related to both stress and abnormalities of the urothelial barrier. The recommended approach to managing these cases is to reduce the cat's stress, encourage her water intake and enrich the environment (for example reducing boredom in indoor cats). Occasionally analgesics and behaviour- modifying drugs such as amitriptyline are recommended.

Feline UR S7/Ox is beneficial for the following reasons:

- Helps to promote effective urine dilution reducing concentrations of minerals and irritants in the urine - as both wet and dry diets are formulated to increase water intake
- Moderate and safe sodium chloride content (1.2% as fed) in the dry formulation helps encourage increased urine volume and reduced urine specific gravity (SG)
- Helps support the bladder mucosal barrier thanks to natural source of glycosaminoglycans
- Helps reduce inflammation thanks to sources of omega-3 fatty acids

URINE SG AND VOLUME IN CATS FED FELINE UR S7/Ox URINARY OR A CONTROL DIET



Clinical case of idiopathic cystitis successfully managed with Feline UR Sr/Ox Urinary dry food



Flory, a 12 year old neutered male domestic short haired cat, was presented to his vet with dysuria, haematuria and pollakiuria. Clinical examination was unremarkable except for caudal abdominal pain and a small bladder.

Abdominal ultrasonography revealed a small bladder with anechoic contents and an abnormally thickened bladder wall. No calculi were observed. Urine collected by ultrasound- guided cystocentesis had a specific gravity of 1.045, pH 7- 8, large numbers of red and white blood cells but no crystals. Urine culture was sterile.

Given the clinical signs of FLUTD with normal urine specific gravity and an absence of crystals or bacteria in the urine, a diagnosis of **idiopathic cystitis** was made. Management included Meloxicam for its anti-inflammatory and analgesic properties (subcutaneously on day 1 then orally for 3 days) and a diet change to encourage increased water intake. Although normally a wet diet is recommended for idiopathic cystitis cases to increase water intake, increase urine volume and reduce urine concentration, in this case- Feline UR Sr/Ox Urinary dry diet was prescribed because Flory's vets were concerned that changing him from his usual dry diet to a wet diet would increase stress- and also because the dry version of Feline UR Sr/Ox Urinary is formulated to encourage drinking and thereby increase urine volume.

Flory took to the new food very well. **An abdominal ultrasound scan performed 1 month after start of treatment revealed no abnormalities and in the three month follow up period, Flory displayed no further urinary symptoms.** Feline UR Sr/Ox Urinary dry had also led to his urine specific gravity reducing to 1.030.

Feline UR St/Ox Urinary is beneficial in reducing recurrence of struvite and calcium oxalate and in dissolving struvite uroliths

Urolithiasis occurs when the urine becomes supersaturated with calculogenic material leading to subsequent crystal and urolith formation. Age, gender, bodyweight, genetics, concurrent diseases and presence or absence of various promoters or inhibitors of uroliths also seem to play a part in determining an individual's susceptibility to developing calculi. Formation and dissolution of struvite stones is also sensitive to urine pH (but calcium oxalate stones are much less influenced by urine acidity).

It helps manage urolithiasis cases because it:

- Promotes the production of urine undersaturated for struvite and in the low metastable range for calcium oxalate to prevent *de novo* crystallisation of calcium oxalate and struvite and dissolution of struvite
- Helps to prevent both struvite and oxalate stones - Reduced urine mineral concentrations and urinary RSS (Relative Supersaturation and APR (Activity Product Ratio) values
- Helps to promote effective urine dilution reducing concentrations of minerals and irritants in the urine - Wet and dry diets both formulated to increase water intake

In addition Feline UR Sr/Ox Urinary contains moderate fat and calories to help maintain an ideal body weight because obesity increases the risk of FLUTD. It is also highly palatable and comes in multiple varieties ensuring long term compliance.

Feline UR Sr/Ox Urinary - proven benefits in the management of struvite stones in general practice

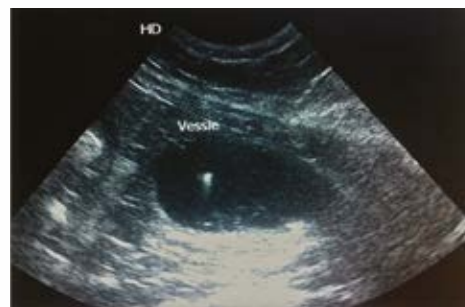

A case of struvite microcalculi successfully managed by Feline UR Sr/Ox Urinary

Chipie was a 6 year old neutered female domestic short haired cat who presented with a 5 day history of abnormal urination (increased frequency, abnormal locations, pink- tinged). Chipie was significantly overweight.

Clinical examination was normal other than mild caudal abdominal discomfort. Urinalysis revealed specific gravity 1.055, pH6.0, red blood cells and struvite crystals. Urine culture was negative. Abdominal ultrasonography revealed an irregular bladder wall with a substantial quantity of microcalculi seen with a "snowstorm" effect on bladder manipulation. A diagnosis of FLUTD caused by struvite microcalculi was made. Treatment with the anti inflammatory drug Meloxicam for 6 days was prescribed and the diet was changed to Feline UR Sr/Ox Urinary dry.

The owners reported that clinical signs resolved almost immediately the diet was changed. At 1 month, ultrasound of the bladder revealed no abnormalities and whilst the urine specific gravity was still 1.050, there were no crystals observed.

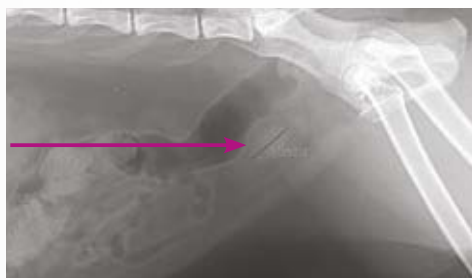

Microcalculi in suspension in the urine

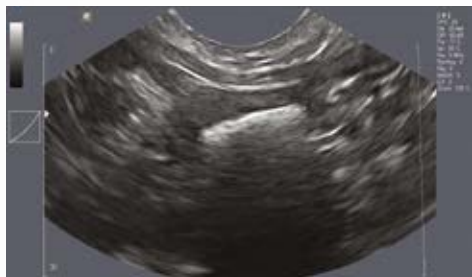A case of Struvite urolithiasis effectively managed with Feline UR St/Ox Urinary wet and dry

Bibouille, a 7 year old neutered female domestic short haired cat was presented to her vet with a 2 year history of intermittent haematuria and urinary soiling. She had also started leaking urine in her sleep. Urolithiasis had been diagnosed one year previously but surgery had been declined by the owners. Clinical examination revealed Bibouille to be underweight and in poor general health with a dull coat. Palpation of the bladder was painful with a grinding sensation noted and the bladder was small and hard. Urinalysis revealed a urine SG of 1.020, pH8.8 and numerous struvite crystals. Urine culture grew E. Coli (1000 colonies/ ml). Radiology and ultrasound of the bladder revealed the presence of a 15mm urolith within the bladder lumen along with hypertrophy of the bladder wall.

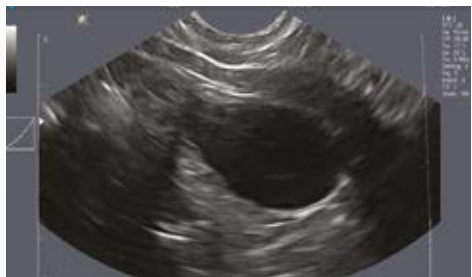A diagnosis of struvite urolithiasis and urinary tract infection was made. A 10 day course of Marbofloxacin was prescribed to treat the urinary tract infection and Feline UR St/ Ox (mixture of wet and dry varieties) was given to dissolve the urolith. One month later, Bibouille had no further clinical signs. The dysuria, haematuria, soiling and incontinence had all disappeared. Radiological and ultrasound investigations were normal- the bladder stone had completely disappeared. 4 months later Bibouille was still clinically normal.



Radiograph of Bibouille at Day 0, showing a unique cystolith of 15 mm of diameter.



Ultrasound scan of Bibouille's bladder at D0, showing a cystolith.



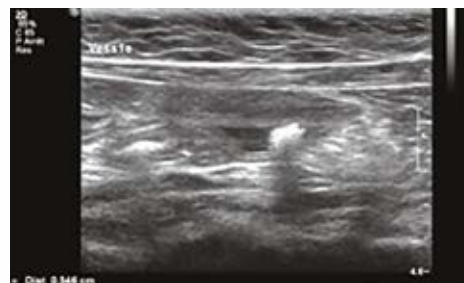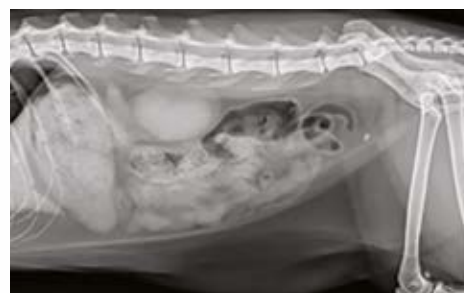Ultrasound scan of Bibouille bladder D0+ 4 months.

Feline UR St/Ox Urinary - proven benefits in the prevention of recurrence of calcium oxalate in general practice

A case of calcium oxalate urolithiasis managed successfully with Feline UR St/Ox Urinary

Balzac was a 5 year old neutered male domestic short haired cat who presented with a 3 year history of recurrent urinary problems (pollakiuria, stranguria, haematuria and urinary soiling). A struvite- dissolving diet had previously been tried with no success. Clinical examination was unremarkable. Bladder palpation was apparently painless and the bladder was small. Urinalysis revealed specific gravity 1.032, pH 6.0, red blood cells but no crystals in sediment. Abdominal radiography and ultrasound revealed a 15mm radio opaque object in the bladder- with a thickened bladder wall also observed.

Given the radio opacity of the urolith, the lack of response to the previous diet and the acidic urine pH a calcium oxalate urolith was suspected and surgical removal was recommended and carried out. Analysis of the stone confirmed it as calcium oxalate- 60% calcium oxalate dihydrate and 40% calcium oxalate monohydrate. Feeding with Feline UR St/Ox Urinary was recommended to prevent recurrence. Meloxicam was also given for 3 days as an analgesic. Other than one episode of mild pollakiuria and haematuria within 2 weeks of surgery which resolved with urinary muscle relaxants (alfuzosin and dantrolene) Balzac remained asymptomatic. At 2 month follow up, urinalysis revealed specific gravity 1.050, pH7.5 and no sediment. Ultrasound was normal.



Calculus in bladder pre operatively

In conclusion, Feline UR St/Ox Urinary wet and dry are highly effective in managing all 3 common causes of FLUTD (idiopathic cystitis, struvite and calcium oxalate urolithiasis). Owners of these cases reported that both wet and dry formulas had exceptional palatability which aided compliance.