



This case report demonstrates the successful use of PURINA® PRO PLAN® VETERINARY DIETS Feline UR St/Ox Urinary wet and dry in the dietary management of Feline Low Urinary Tract Disease (FLUTD) in a cat.

A case of struvite bladder stones in a 4-year-old neutered male cat

Dr Christelle Maurey

(Lecturer, Department of Medicine),
Alfort National School of Veterinary Medicine, Maisons-Alfort, France

Gary was a 4-year-old neutered male domestic short haired cat who lived in a flat and was fed Whiskas™ Dry food. For 4 years, Gary had had three episodes of lower urinary tract disease, one of which involved obstruction with the presence of struvite crystals. The urethra was catheterised and the catheter left in place for 48 hours while intravenous fluid therapy was given. Additionally, a special diet was prescribed, but this was not given by the owner.

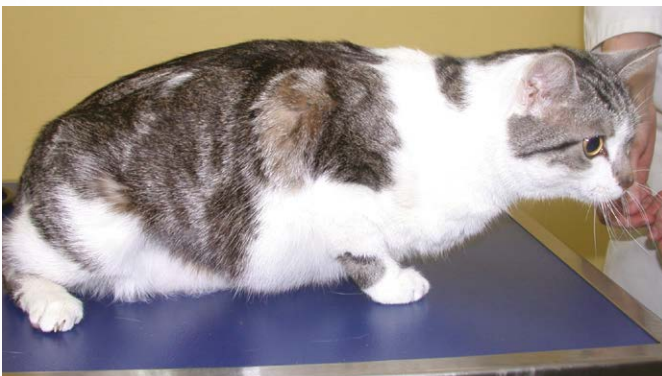

Figure 1: Gary during his initial examination

Clinical examination

The clinical examination revealed that Gary was in good general condition with a body condition score of 4/5. He weighed 5kg, and his vital signs were normal. Discomfort was exhibited on palpation of the bladder and Gary exhibited pollakiuria and stranguria.

The clinical presentation and history thus indicated a 4-year-old neutered male domestic short haired cat in good general condition with recurrent episodes of obstructive or non-obstructive feline lower urinary tract disease associated with the presence of struvite crystals.

Further examinations

The differential diagnoses based on the history and clinical examination included urolithiasis, idiopathic cystitis, urinary mucus plugs and bacterial infection. A lower urinary tract tumour or a congenital malformation could not be ruled out but were less likely.

a. Blood tests

The laboratory tests revealed no abnormalities.

b. Urinalysis

Examination of the urine revealed a urinary specific gravity of 1.035, microscopic haematuria and a large number of struvite crystals. The urine culture was negative.

c. Radiology and ultrasound report

The ultrasound scan revealed the presence of two small bladder stones and echogenic material adhering to the wall. The bladder wall was also thickened (Figure 2). Abdominal radiography revealed no significant abnormalities. (Figure 3).

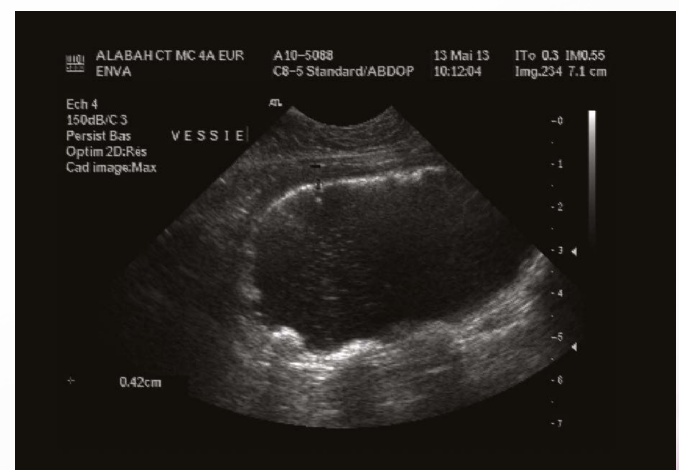


Figure 2: Abdominal ultrasound of Gary at T0

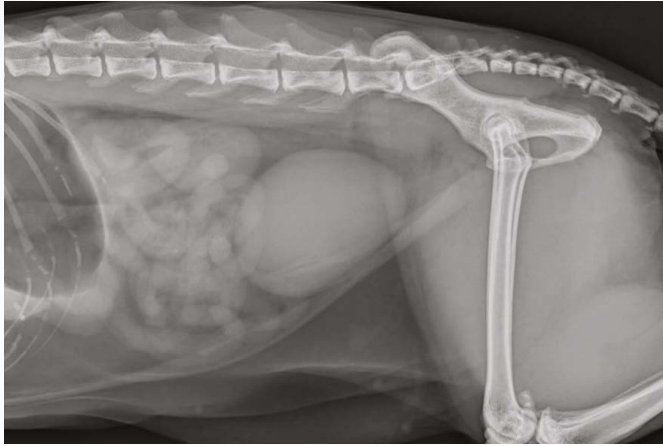


Figure 3: Radiography of Gary at T0

Discussion and conclusion

Uroliths are the second most common cause of lower urinary tract disease in cats. Although struvite stones have decreased in frequency in recent years compared with calcium oxalate stones, they are still quite common. Diet plays a key role in their prevention and treatment. Indeed, the availability of stone-dissolving diets reduces the need to resort to more invasive treatments and to surgery in particular.

Diagnosis

The results of the urinalysis and the ultrasound scan suggested the presence of struvite stones.

Therapeutic measures and follow-up

Gary was put on PURINA® PRO PLAN® VETERINARY DIETS Feline UR St/Ox Urinary in dry form. He refuses wet food, but is eating his new dry food very well. The follow-up examination conducted 2 months later showed an animal in good general condition without any urinary problems. The ultrasound examination of the bladder showed the stones and echogenic material to have disappeared. The bladder wall was normal (Figure 4).

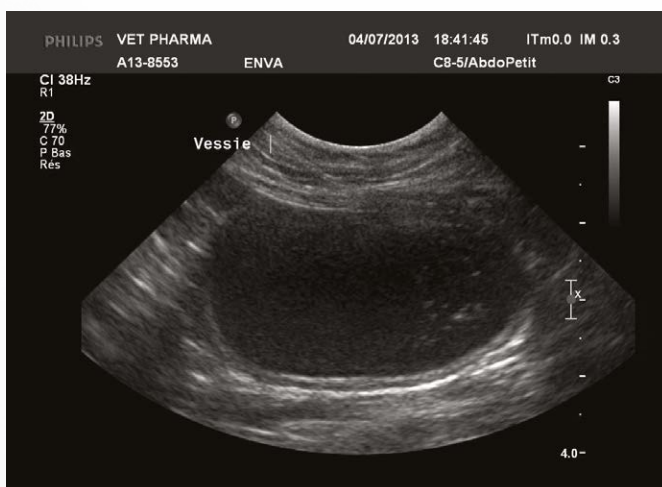


Figure 4: Ultrasound image at T+ 2 months