

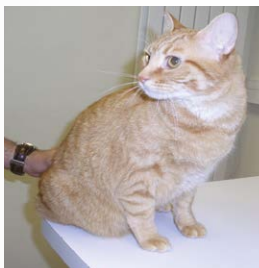

This case report demonstrates the successful use of PURINA® PRO PLAN® VETERINARY DIETS Feline UR St/Ox Urinary wet and dry in the dietary management of Feline Low Urinary Tract Disease (FLUTD) in a cat.

## Feline Low Urinary Tract Disease (FLUTD) in a male cat

### Dr Fradin-Fermé

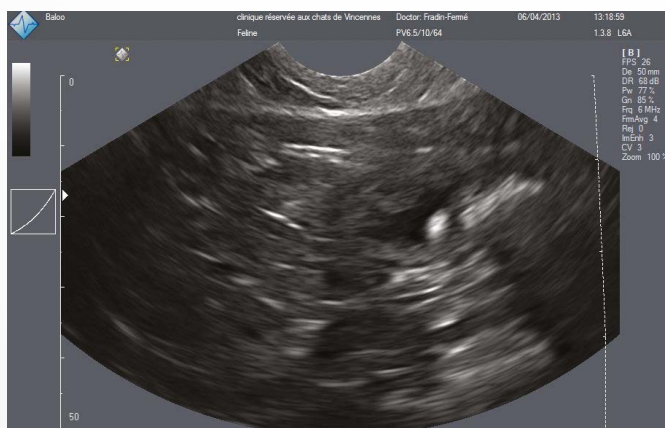
Feline exclusive veterinary practitioner  
in Vincennes, France



Baloo, a 2-year-old castrated male domestic cat, was brought in to the clinic with a three-day history of dysuria and haematuria. He was living in an apartment with another cat, in a childless household. Baloo was receiving a grocery dry food and occasional canned food.

### Clinical examination

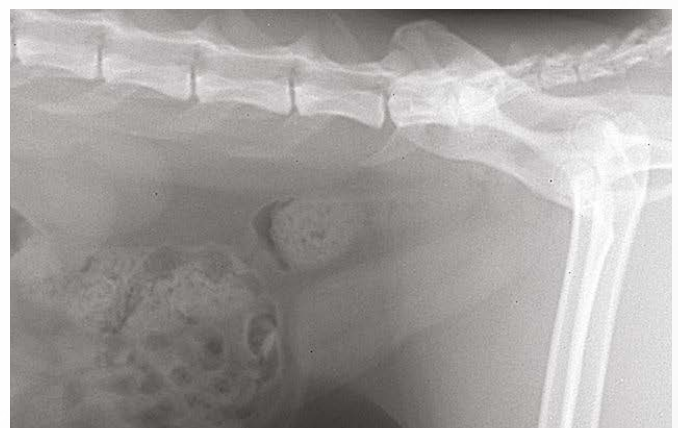
The clinical examination did not reveal any abnormalities: Baloo was in a good general state of health and weighed 7.530 kg. Because the bladder was empty, no urine sample was taken. The cat was treated symptomatically for three days using antispasmodics and anti-inflammatories.



Ultrasound scan of Baloo's bladder at D0, showing a hyperechoic mass.

### Additional examinations and diagnosis

Additional examinations were performed on Day 4. The bladder was moderately distended. Radiological investigations were normal, with no bladder or kidney stones identified. On ultrasound, a hyperechoic mass was observed in the bladder lumen. In the absence of a shadow cone, this was considered likely to be a blood clot. The bladder wall was thickened. A urine sample was taken by catheterisation (without tranquillisation). The urine was macroscopically normal. Urinalysis performed at the clinic revealed the presence of red blood cells and calcium oxalate crystals. The pH was 6.0 and urinary specific gravity 1.032. The remaining urine was submitted to two different laboratories. One confirmed the presence of **oxalate crystals and blood**, whilst the other analysed the sediment six days after sample collection and found occasional red blood cells, but no crystals. Urine culture was negative. Blood tests were normal. Despite the presence of oxalate crystals, serum calcium levels were normal.



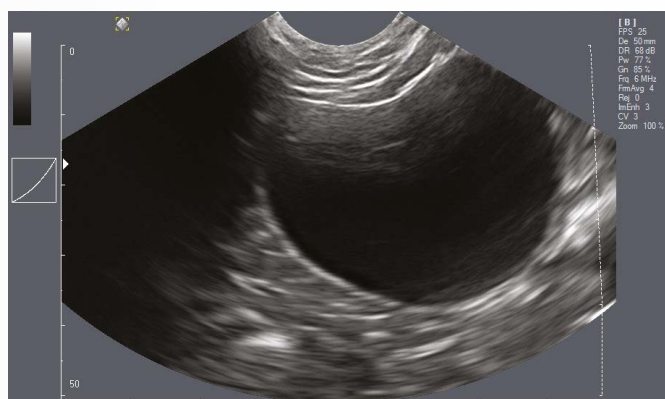
Radiograph of Baloo's abdomen at D0.

**PURINA®**  
**PRO PLAN®**  
**VETERINARY**  
**DIETS**

## Treatment and follow-up

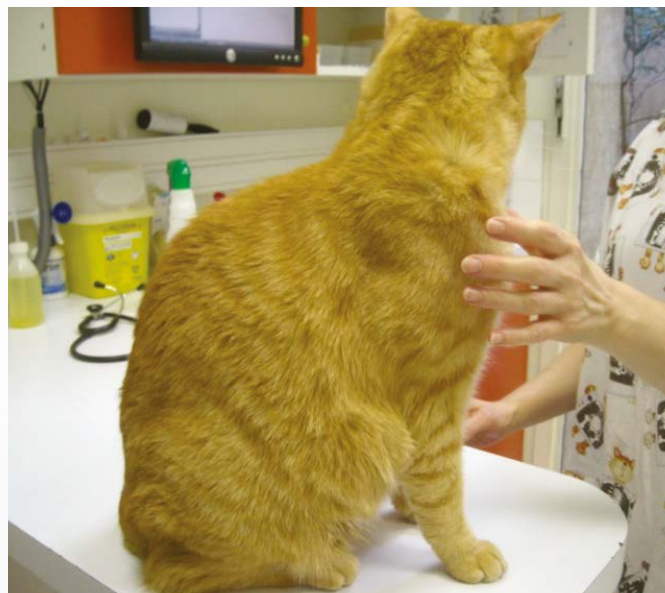A mixed combination (can and dry food) of PURINA® PRO PLAN® VETERINARY DIETS Feline UR St/Ox Urinary was then prescribed.

At the follow-up visit on D0 + 2 months, Baloo was asymptomatic. He weighed 7.680 kg and had therefore gained 150 g. He had no further difficulty in urinating, the problem having resolved itself within a week. Radiological investigations were normal.



*Ultrasound image of Baloo's bladder at D0+2 months: the image does show a normal and healthy bladder.*

On ultrasound, the bladder wall was thin and even, and the bladder well-distended. The urine appeared clear.



*Baloo at D0+ 4 months.*

A urine sample was collected by cystocentesis. Its macroscopic appearance was normal, the pH was 7.0 and the specific gravity 1.052. The only finding was a few epithelial cells.

At the visit on D0 + 4 months, Baloo was asymptomatic. However, he had put on a lot of weight. He now weighed 8.120 kg, having gained 590 g since his first visit.

Radiological and ultrasound investigations were normal. Because the bladder was full, urine was collected by cystocentesis. The pH was 7.0, urinary specific gravity at 1.029 was lower than on previous visits, and examination of the sediment did not reveal any crystals. Blood tests were normal.

## Discussion and conclusion

Apart from the weight gain, the diet was clearly beneficial in Baloo's case. The weight gain might be explained by the fact that he was living with another cat that was eating the same food in order to maximise the chances of success for Baloo's dietary management. The owner had had trouble monitoring each cat's intake. It was therefore possible that Baloo had been eating more than his intended ration.

Baloo's owner was delighted with the results and planned to continue giving both cats this food, which he considered to be good value for money.