



This case report demonstrates the usefulness of PURINA® PRO PLAN® VETERINARY DIETS Feline UR St/Ox Urinary (dry) in the treatment of lower urinary tract disease in the cat.

A case of cystitis associated with struvite microcalculi

Dr Amélie Nègre

*Clinique Vétérinaire des Remparts,
Pontoise, France*

Introduction

Chipie was a six-year-old female domestic cat who was brought in for consultation in the spring with urination problems.

She lived in an apartment with no other cats and never went outdoors. She was generally inactive as she was not very playful and slept a lot. Her owners described her as 'stressed'; she would hide when strangers arrived.

She was fed *ad libitum* on wet and dry food from the supermarket, and had a normal appetite. She was spayed but not vaccinated.

Clinical examination

At the initial consultation, the owners described abnormal urination over the past five days. Chipie had been passing urine more often than usual and spending time scratching in her litter box. She had urinated beside the box several times, which revealed a pink tinge to the urine.

This was Chipie's first episode of urinary problems, and until then she had had no history of significant health issues.

On clinical examination, Chippie was somewhat glued to the table and rather uncooperative. She was a small-framed cat but weighed 4.9 kg (indicating that she was significantly overweight, which was confirmed on palpation). The caudal abdomen was slightly sensitive, especially the bladder. The rest of the examination was normal.



Photo 1: Chipie

Additional examinations

The following supplementary examinations were performed in order to establish a diagnosis:

Abdominal ultrasound

On ultrasound examination, the bladder contained a normal volume of urine. The bladder wall was irregular; the ventral section in particular was abnormally thickened (up to 1 cm). No masses were detected in the neck or wall of the bladder (*photo 2*).

After joggling the probe to mobilise the bladder, multiple dot-like hyperechoic images were observed in the bladder contents, resembling a 'snowstorm' effect: these images are compatible with the presence of microcalculi in suspension in the urine (*photo 3*).

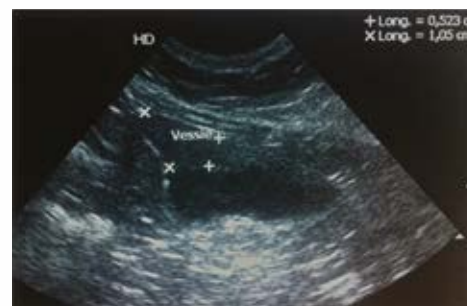

Photo 2: thickening of the bladder wall

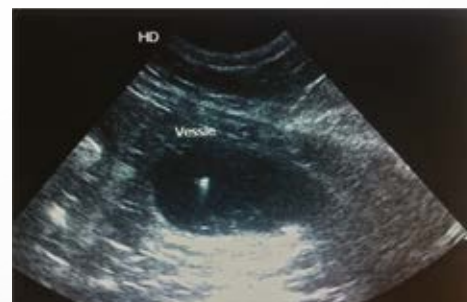

Photo 3: uroliths in suspension in the urine

No individual stones of significant size (characterised by a hyperechoic image accompanied by a shadow cone) were detected in either the bladder or the kidneys.

The ultrasound appearance of the kidneys was normal (*photos 4 and 5*). The ureters were not visible, which is normal if they are not dilated (e.g. obstructed by a ureteral calculus).

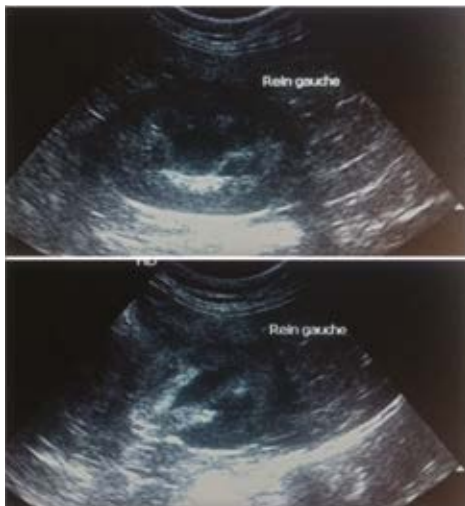

Photo 4: front and side view of left kidney (normal appearance)

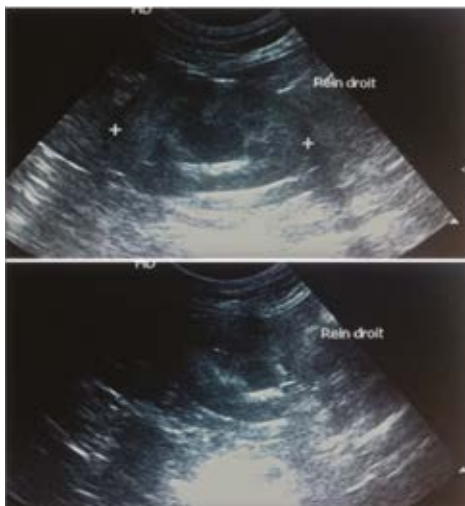


Photo 5: front and side view of right kidney (normal appearance)

Abdominal radiography

No calculi were visible in the urinary tract on abdominal radiography (*photo 6*).

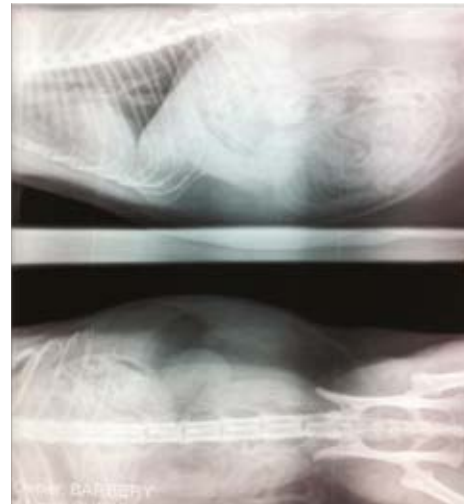


Photo 6: front and side view of abdomen on DO

Urinalysis

The urine specific gravity was over 1.050. The urine test strip indicated a pH of 6 and the presence of blood (++++). The urinary sediment showed the presence of red blood cells (++++) and struvite (magnesium ammonium phosphate) crystals (++) (*photos 7 and 8*). No organisms were detected on cytobacteriological examination of urine collected in a borate tube by ultrasound-guided cystocentesis and dispatched the same day.

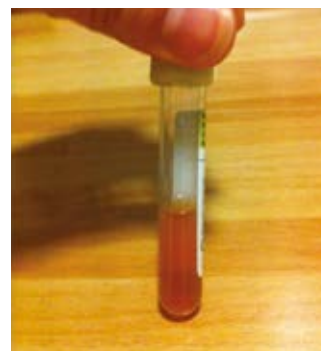

Photo 7: haematuria



Photo 8: urinary sediment

Blood tests

Haematology and biochemistry revealed no abnormalities.

Management and follow-up

Diagnosis

All of the data collected (case history, clinical examination and results of additional examinations) led to a diagnosis of cystitis associated with struvite microcalculi.

Treatment

To relieve the lower urinary tract inflammation, an injection of an anti-inflammatory drug (Metacam®) was given during the initial consultation, followed by a prescription for continuing oral administration at home for six days (Metacam®).

Because struvite microcalculi irritate the bladder wall, Feline UR S₇/Ox Urinary (dry) was prescribed in order to dissolve the existing microcalculi and crystals and to prevent new crystals from forming. The owners were reminded that Chipie should not eat anything other than the prescribed diet.

Follow-up

- Clinical examination - D0 + 1 month:

Chipie's general condition was good. The owners reported that the urinary symptoms had disappeared as soon as the dietary treatment was initiated. The dietary transition had gone well, without any digestive problems. Chipie was enjoying the Feline UR S₇/Ox Urinary (dry), which was being fed *ad libitum*. On being weighed, she was found to have gained 800 grams in a month.

- Additional examinations - Follow-up ultrasound

The bladder was of normal appearance, especially the bladder wall, which was no longer thickened. There were no longer any particles suspended in the urine (*photo 9*).

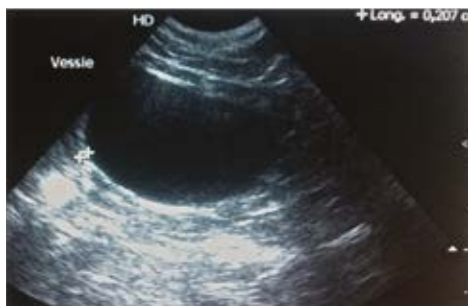

Photo 9: bladder at D0 + 1 month

- Urinalysis

The urine was still well-concentrated (urine density >1.050). The urine test strip did not reveal any blood. Protein was still present (+) and the pH was 7. No struvite crystals were found in the urinary sediment on microscopic examination.

- Prescription

Chipie was to continue her exclusive diet of Feline UR S₇/Ox Urinary (dry) in order to avoid a recurrence of crystalluria. However, her intake was rationed to 50 grams per day in order to minimise weight gain.

- Clinical examination - D0 + 2 months:

Chipie was still happily eating Feline UR S₇/Ox Urinary (dry) and had lost 450 grams due to the rationing. No recurrence of urinary symptoms was reported.

- Additional examinations - Follow-up ultrasound

The appearance of the bladder wall and urine was normal. No calculi were observed (*photo 10*).

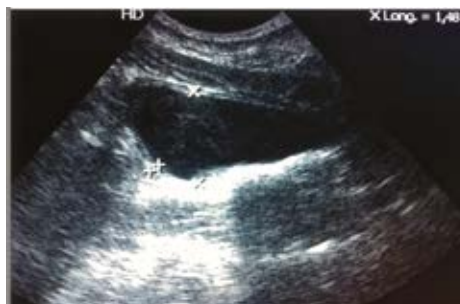

Photo 10: bladder at D0 + 2 months

- Urinalysis

Refractometry indicated that the specific gravity was still high (>1.050). The urine test strip showed a stable pH of 7. No crystals and only occasional cells were observed in the urine sediment.

- Blood tests

Haematology and biochemistry revealed stable values within the normal range.

 **PURINA**[®]
PRO PLAN[®]
VETERINARY
DIETS

Discussion and conclusion

In this case of cystitis associated with struvite crystals, Feline UR S₁/Ox Urinary proved very effective. It took only a few days of treatment with non-steroidal anti-inflammatories to alleviate the significant inflammation of Chipie's bladder wall and to enable her to urinate comfortably again. The remainder of treatment was provided by the veterinary diet, which quickly (in less than four weeks) dissolved all of the struvite crystals responsible for the significant bladder wall inflammation.

Tolerance and palatability were excellent, as Chipie adopted and enjoyed the new dry food immediately without any digestive problems and did not tire of it.

The owners, who had been very upset at the initial consultation, returned for the two check-ups with smiles on their faces. They clearly expressed their satisfaction with the effectiveness and simplicity of the treatment put in place. They had initially been afraid that Chipie, a cat they described as 'difficult and demanding', would not accept the change of food. But, from the first check-up, they stressed that she was enjoying the Feline UR S₁/Ox Urinary (dry). The weight gain observed during the consultation, with *ad libitum* feeding, is evidence of its palatability.

When asked if they would recommend this diet to other cat owners, they responded in the affirmative, stressing that the transition had been easy in every respect (palatability and digestive tolerance) and appreciated the ease of treatment just with a diet, rather than with several types of medication that might not always be easy to administer.

I regularly prescribe Feline UR S₁/Ox Urinary (dry) and recommend it to my professional colleagues, as it not only treats both struvite and oxalate crystals but also plays a role in healing and strengthening the bladder wall. Moreover, as in Chipie's case, palatability and tolerance are generally very good, even in cats regarded as 'difficult'.