



This case report demonstrates the usefulness of PURINA® PRO PLAN® VETERINARY DIETS Feline UR St/Ox Urinary (dry) in the treatment of lower urinary tract disease in the cat.

## A case of idiopathic cystitis

### Drs Ducluzaux and Pereira

Veterinary clinic, route de Romans 53, 26120  
Chabeuil, France

### Introduction

Flory was a 12-year-old castrated male domestic cat, adopted five years previously, who lived in a house with free access to the outdoors. His diet consisted mainly of supermarket dry cat food. He had no known history of major illness. He was brought in for consultation with dysuria, haematuria and pollakiuria.

### Clinical examination

Flory was in excellent general condition (*photo 1*). His rectal temperature was 38.3 °C. Abdominal palpation was painful in the caudal region and the bladder was small on palpation.



Photo 1 : Flory at the vet clinic

### Additional examinations

Due to the clinical signs of feline lower urinary tract disease (FLUTD), the first examination performed was a bladder ultrasound with ultrasound-guided cystocentesis. The images showed a bladder with a small volume of anechoic contents and an abnormally thickened bladder wall (0.5 cm). No calculi were observed (*photo 2*).

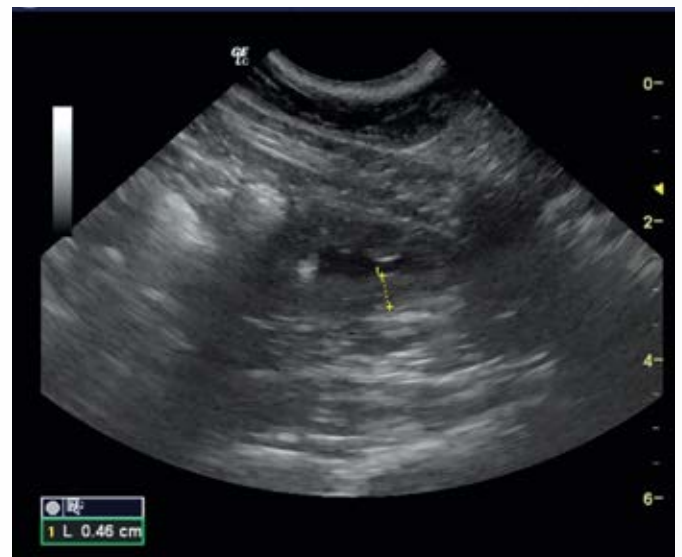


Photo 2 : Ultrasound image of Flory's bladder showing a thickened bladder wall

Urinalysis revealed a urine density of 1.045, a pH between 7 and 8, large numbers of red and white blood cells, and an absence of crystals. Urine culture was sterile.

Biochemistry results and blood counts were normal.

## Diagnosis

Given the presence of signs of FLUTD with normal urine density and in the absence of crystals or bacteria in the urine, a diagnosis of idiopathic cystitis was made.

## Management and Follow-up

For pain relief and for its anti-inflammatory effect, meloxicam was administered subcutaneously on the first day, and then orally for three days (0.05 mg/kg/day).

The diet was switched to Feline UR S<sub>1</sub>/O<sub>x</sub> Urinary (dry) and drinking was encouraged by increasing the number of water sources available and by using large bowls.

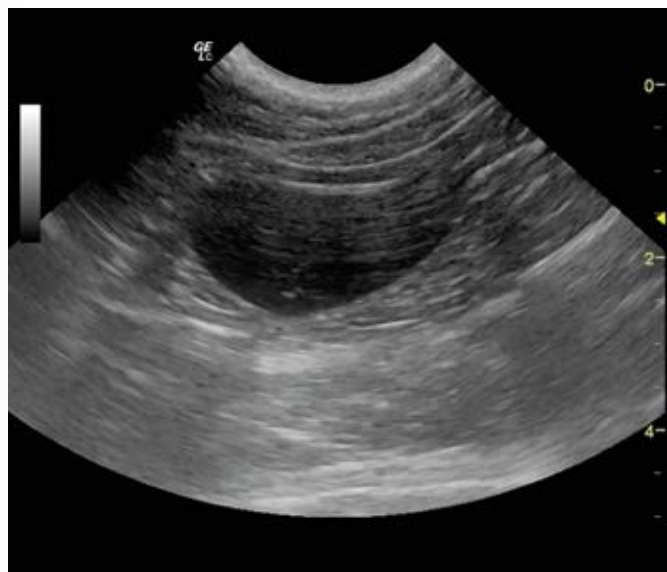

Photo 3 : Ultrasound image of Flory's bladder after one month

A month after the start of treatment, Flory had had no further episodes of dysuria. A bladder ultrasound showed no abnormalities; the bladder contents were anechoic, the wall was thin and no calculi were observed (photo 3). Urinalysis also revealed no abnormalities.

A second follow-up visit took place three months after the start of treatment. Bladder ultrasound and urinalysis showed no abnormalities. Urinary density was 1.032 and the pH was 6.5.

## Discussion and conclusion

When faced with symptoms of FLUTD in an older cat such as Flory, it is important to rule out conditions causing a reduction in urine density (chronic renal insufficiency, hyperthyroidism, *diabetes mellitus*), which promote urinary infections. The other causes of FLUTD (principally calculi and, in rare cases, malformation) should then be considered. Once all other causes have been ruled out, the diagnosis of idiopathic cystitis can be made by elimination. This condition remains the most common cause of FLUTD. It is very rare for a first episode of cystitis to occur after the age of ten. Flory's medical history was unknown, so it could be assumed that this was not his first episode.

The management of this condition is based on medication (principally NSAIDs), behavioural measures (reducing stress and anxiety) and dietary adjustments. The majority of authors agree that wet food is most appropriate, but the crucial point is to encourage drinking, which lowers urine density and thus reduces bladder inflammation. In this case, we chose Feline UR S<sub>1</sub>/O<sub>x</sub> Urinary (dry), partly in order to avoid too many changes and so to minimise stress for Flory, but also because of the diet's ability to encourage drinking and thus increase the volume of urine produced in 24 hours. The diet also contains long-chain omega-3 fatty acids with anti-inflammatory properties, and sources of glycosaminoglycans which help to regenerate the bladder epithelium. A dietary transition was implemented over five days and Flory took to his new food very well. During the three-month follow-up, this diet, combined with the management measures put in place, proved effective in controlling Flory's idiopathic cystitis. He displayed no further urinary symptoms and his urine density was around 1.030. Idiopathic cystitis is a recurring chronic condition with underlying mechanisms that remain poorly understood. Recurrences are common but, with the dietary and behavioural measures put in place, it is hoped to minimise the frequency and severity of episodes of cystitis.